

UDC 94(32):572

**APPLICATION OF SMART INFORMATICS IN EGYPTOLOGY:
THE ATHENS MUMMY PROJECT AS AN EXAMPLE
OF EFFECTIVE INTERDISCIPLINARITY**

A. Maravelia

PhD (Egyptology); PhD (Astronomy & Astrophysics)

Hellenic Institute of Egyptology, Athens, Greece

hieg-aker.org@otenet.gr

N. Bontozoglou

PhD (Medicine), MD, Athens Medical Centre

Athens, Greece

K. Kalogerakou

MD, Athens Medical Centre

Athens, Greece

C. M. Couvaris

MD, Forensic Pathologist

ICRC, Athens & Hellenic Institute of Egyptology

Athens, Greece

S. Geroulanos

Em. Prof., PhD (Medicine)

International Hippocratic Foundation & Hellenic Institute of Egyptology

Kos & Athens, Greece

© 2019 A. Maravelia, N. Bontozoglou, K. Kalogerakou, C. M. Couvaris, S. Geroulanos; Published by the A. Yu. Krymskyi Institute of Oriental Studies, NAS of Ukraine on behalf of *The Oriental Studies*. This is an Open Access article distributed under the terms of the Creative Commons Attribution License (<https://creativecommons.org/licenses/by-nc-nd/4.0/>).

We present the *Mummy Project* of the *Hellenic Institute of Egyptology* (HIE), in close collaboration with the *National Archaeological Museum of Athens* (NAM) and the *Athens Medical Centre* (AMC), as a characteristic case of interdisciplinary study and interaction, not only between Smart Informatics (SI) – and to a lesser extent Artificial Intelligence (AI) and (Archaeo-)Medicine, but also with Egyptology and (Archaeo-)Forensics. We discuss some intriguing results of the CT-Scanning for five out of the nine mummies of the Project and emphasize the Informatics used for Computed Tomography (CT) that opens new ways in the study of the conditions, causes of death and other interesting information connected with humans who died in ancient Egypt at least 2,100 years ago, during the Ptolemaic Era. We show clearly that this consists of a characteristic paradigm of interdisciplinary SI application in Medicine and the health of ancient individuals (based on Smart Computing), providing new insights into the egyptological and archaeological consideration of their theocratic society.

Keywords: Ancient Egypt, Mummies, Funerary Customs, CT-Scanning, Non-Invasive Body-Mapping, (Archaeo-)Medicine, (Archaeo-)Forensics, Smart Informatics, Artificial Intelligence, Interdisciplinarity

I. General Introduction and Acknowledgements: The Mummy Project, the Team of the Mummy Project and our Sponsors

The *Mummy Project* of the *Hellenic Institute of Egyptology* (HIE), in close collaboration with the *National Archaeological Museum of Athens* (NAM) and the *Athens Medical Centre* (AMC), is related to the complete study of nine anthropoid sarcophagi and their mummies, dating from the Ptolemaic Period, kept at the NAM [Maravelia, Bontozoglou *et al.* 2015, 32–33]. The Egyptian Collection of the NAM (re-opened in 2008 with an exhibition of more than 1200 objects from more than 7000 owned) keeps most of its treasures well hidden in the Museum's storerooms. Among those, we have managed to rediscover some Ptolemaic Period coffins with their mummies. Now, a new generation of well-qualified Egyptologists, with the Museum's collaboration (**Fig. 1**), brings to light these forgotten and more or less unknown artefacts. These coffins were found in Egypt (Panopolis, modern Akhmīm) and were donated to the Hellenic Government during the late 19th Century by wealthy patriots who lived there.

Our Team (**Fig. 1**) is an interdisciplinary group of experienced scholars, conservators, medical and (forensic) doctors, who came

together to make this Research Project feasible for the first time in Hellas. The Members of the Team are the following: **1. Prof. Dr Dr Alicia Maravelia:** Founder and Director of the HIE and Professor at the People's University of Athens; **2. M^{rs} Helen Tourna:** Curator of the Egyptian Collection of the NAM and former Asst. Secretary of the HIE; **3. Dr Nikolaos Bontozoglou, MD:** Radiologist, Director of the CT-Scanning Team and Unit of the AMC and Member of the HIE; **4. M^r Panaghiotis Lazaris:** Conservator of the Egyptian Collection of the NAM; **5. Em. Prof. Dr Stephanos Geroulanos:** Cardiologist-Histopathologist, President of the International Hippocratic Foundation and Founding Member of the HIE; **6. M^r Constantinos M. Couvaris, MD:** Forensic Pathologist and Anthropologist, Forensic Consultant for ICRC in Athens and Member of the HIE; **7. M^{rs} Stauroula Kyriazi, MD:** Radiologist and Member of the CT-Scanning Team and Unit of the AMC; **8. M^r Ioannis Pantazis, MD:** Radiologist and Member of the CT-Scanning Team and Unit of the AMC, Dental Specialist; **9. M^r Kyriakos Kalampoukas, MD:** Radiologist and Member of the CT-Scanning Team and Unit of the AMC; **10. M^{rs} Kleanthi Kalogerakou, MD:** Radiologist and Member of the CT-Scanning Team and Unit of the AMC; **11. Dr Georghios Michailidis, MD:** Radiologist and Member of the CT-Scanning Team and Unit of the AMC.

The purpose of our Mummy Project is to demonstrate the importance of these forgotten sarcophagi and to present a complete and precise Egyptological, medical and forensic study of their mummies. These anthropoid coffins and their hieroglyphic inscriptions were thoroughly examined and published [Maravelia, Cladaki 2004; Maravelia 2005]. The fact that at least half of the mummies belonged to higher class individuals, mainly related to the local priesthood¹ is by itself quite promising, since it will let us comparatively conclude on the social conditions of health, the causes of death, the various illnesses or syndromes they were suffering from, their teeth-conditions and subsequently their dietary habits, as well as the lives of these ancient humans who lived during the swan-song era of Pharaonic Egypt.

¹ E.g.: the cases of a dancing-priestess of Min, another noble lady, a noble man and two children.

The principal scope of this Project is the medical, anthropological, forensic, anatomical and histopathological examination of the mummies (a statistically complete archaeo-anthropological set, including human remains of various ages and of both sexes)², using modern medical, radiological and forensic techniques that are firmly based on Smart Informatics (SI), namely on Smart Computing.

On Saturday 22nd October 2016 (**Fig. 2–3, 14**) at the premises of AMC – and with the help of all the aforementioned participants and sponsors (see Acknowledgments) – the scanning of 5 out of the 9 mummies took place successfully and by now (October 2019) the study of the results is complete and four papers have been already sent for publication in distinguished medical/radiological and egyptological journals. Extremely interesting and intriguing medical and anthropological findings have been uncovered and some of them will be here discussed in detail. In some cases we have detected rare syndromes that have never been reported in the international bibliography until now, and other interesting findings. In the case of the young priestess there are also intriguing results, presenting a puzzle that we try to solve forensically and egyptologically. Later on, a trial for the facial reconstruction of (at least some of) the faces of the mummies will be attempted³. Our results will be compared with ancient Egyptian and Hellenic sources (medical texts in papyri and elsewhere), in order to give a neater insight into the possible correlation of the pathological conditions of the examined individuals with specific cases found in the ancient medical (and/or related) records⁴.

II. Introduction to CT-Scanning and Modern Radiological Techniques supported by Smart Informatics

The evolution of imaging gave scientists the ability to study various mummies in detail, without unwrapping and destroying them⁵. It started with the advent of X-Rays and the first X-rayed mummy in 1896, and evolved with the use of advanced imaging techniques [Harris, Wente 1980]. CT has been used for the study of mummies for al-

² On the sexual identity of mummies and their sexuality in the hereafter, especially during the Helleno-Roman Period, see: [Colazilli 2017, 277–284].

³ Cf. [SGI 2004].

⁴ Cf. [Nunn 1996; Zakrzewski 2014, 57–68].

⁵ See e.g.: [Taylor 1996].

most 40 years and it is considered to be the gold standard for the non-destructive study of ancient mummies [Cramer *et al.* 2018, 225–232; Lewin, Harwood-Nash 1977]. Examining mummies was not without surprises. Sometimes unusual content was found inside the mummy after unwrapping or after imaging it. For more information on mummies studied by CT, the reader is referred to the rich bibliography⁶.

The AMC is using a very modern and competent CT-Scanner (Siemens, Somatom, Healthineers, Erlangen, Germany). This specific model is a Sensation 64, Multi-Detector CT-Scanner, usually scanning at 120 kV and 250 mA·s, and is able to create numerous axial images with a very high precision (the thickness is of the order of magnitude of 0.1 mm). The previous permit anatomic evaluation, measurements and 2D – as well as 3D-image reconstructions, performed on the Multimodality Workstation (Siemens Healthineers, Erlangen, Germany), supported by the Somaris 5 Software. Actually, the Software Syngo CT2014A with ICS/IES VB42B and the support of Windows 5.1 (Build 2600: Service Pack 3) are used for these purposes. As for the reconstructions, a Multimodality Workstation with the Software Syngo MMWP VE40A and Syngo VE32E, supported by Windows WinNT5.2 (Service Pack 2) is also successfully used. Thus, the sample of mummies was examined using non-invasive medical and forensic techniques, mainly applying Computed Tomography (CT), including the up-to-date technology that the AMC is providing (through Siemens and the above mentioned modern, reliable and precise software).

III. Egyptological Introduction to the Mummy Project

As we noted, the NAM⁷ owns a good number of anthropoid sarcophagi dated to the Third Intermediate Period, the Late, Ptolemaic

⁶ E.g.: [Chan, Elias *et al.* 2008, 2023–2032; David 1990; Germer 1991; Aufderheide, Zlonis *et al.* 1999, 197–210; Zweifel *et al.* 2009, 405–427; Guilhous, Perraud 2010; Loynes 2015; McKnight *et al.* 2014, 97–107; McKnight *et al.* 2015, 2108–2120; Raven, Taconis 2005; Taylor, Antoine 2014; Walker, Bierbrier 1997; Uranić 2012; Piombino-Mascali, Jankauskas *et al.* 2013–2014, 71–79; Piombino-Mascali, Jankauskas *et al.* 2016, 69–79; Klaes 2014, 55–80].

⁷ For a concise introduction to the Egyptian Collection of the National Archaeological Museum of Athens, see [Maravelia 2002, 15–29], where relevant bibliography is given.

and Roman Periods. M^r Ioannēs Dēmētriou donated them to the Hellenic Kingdom in 1884. He acquired ten of these sarcophagi from Akhmīm. They were found in excavations by Dr Gaston Maspero (1884) at the Necropolis of Khemmis (Cemetery A) and were officially purchased by that wealthy patriot, who offered them to the newly inaugurated NAM [Neroutsos 1884, *col. 172 & n. 3*; cf. *IIAE* 1884, 25; Kuhlmann 1983, 50–61]. The sarcophagi containing the mummies studied and scanned are the following: **1. NAM AIG 3342:** Thau (*T3w*): ♂, c. 304–150 BC; **2. NAM AIG 3343:** Sekhem (*Shm*): ♂, c. 150–30 BC; **3. NAM AIG 3344:** Tekha or Tekhtyou or Tekh-Horus (*Th3* or *Thtyw* or *Th-Hr*): ♂ child, c. 150–30 BC; **4. NAM AIG 3346:** Ta-di-thed-Amūn (*T3-di-ṯd-Imn*): ♂, c. 150–30 BC; and **5. NAM AIG 3348:** Ta-khered-Min (*T3-hrd-Mnw*): ♀, c. 304–150 BC. The studied sarcophagi with the as yet un-scanned mummies are the following: **6. NAM AIG 3340:** Hapy (*Hpy*): ♂, c. 304–150 BC; **7. NAM AIG 3341:** Ta-Redi-Bastet (*T3-rdi-B3stt*): ♀, c. 304–150 BC; **8. NAM AIG 3345:** Semen-Nefer (*Sm-nfr*): ♂ child, c. 150–30 BC; **9. NAM AIG 3349:** Nes-Hor (*Ns-Hr*): ♂, c. 304–150 BC; and **10. NAM AIG 3347:** Ryri (*Ryri*): ♀, c. 304–150 BC (the mummy of this last coffin is very fragmentary and in extremely poor condition, thus it will not be scanned). Their alluded sex is based on the inscriptions of their coffins (**Fig. 4**).

Akhmīm is an area on the east bank of the Nile opposite modern Sohāg. The ancient Egyptians called it *Ipw* (*Ipw*) or *Khent-Min* (*Hnt-Mnw*). For the Copts it was ⲙⲓⲛ or ⲱⲙⲓⲛ, and so the Hellēnes called it *Khemmis* (Χέμμις) or *Panopolis* (Πανόπολις) after the principal god of the city Min, who was identified by them with Pan, the god of fertility and master of the deserts between the Nile and the Red Sea, both being benevolent ithyphallic and/or fertility deities, personifying the male fecundity forces of Nature⁸. It was once a great centre in Egypt and the capital of the 9th Upper Egyptian Nome (Πανοπολίτης). The ancient Necropolis of Akhmīm and its large number of rock-cut tombs that belonged to different dates from the Sixth Dynasty [Browarski 1985] until the Ptolemaic Period, particularly at the 'El-Hawawīsh area, to the North East of Akhmīm and at 'El-Salamūni,

⁸ E.g.: [*LÄ* IV, 1982: cols. 136–140: s.v. “Min”; *BMD* 1996, 187–188: s.v. “Min”; Ogdon 1985–1986, 29–41].

had never been fully excavated⁹. Percy Newberry [Newberry 1912, 101–120] first made an attempt in 1912, but unfortunately most of the findings had been largely plundered during the 1880s. He unearthed several tombs dating from the Late Period, which were recently re-examined and recorded by Prof. Dr Naguīb Kanawāti [Kanawāti 1980–1992]. Prof. Kanawāti¹⁰ believes that these coffins perhaps came from 'El-Salamūni, not far from 'El-Hawawīsh (which was the cemetery of Akhmīm during the Old Kingdom). In his opinion they are all Ptolemaic. He points out however that the area of Akhmīm contains many sites not yet excavated systematically and accordingly the whereabouts of earlier cemeteries, like the Necropolis of the New Kingdom, is uncertain¹¹. The sarcophagi examined here originated from these very tombs (by the late G. Maspero [Maspero 1884, 66–68; 1893, 215 ff; cf. also Kuhlmann 1983, 56–57, n. 281]), then dispersed into the antiquities' market, where they were all subsequently bought by Ioannēs Dēmētriou, who donated them (together with other items) to the NAM.

Dēmētriou granted the study of the Museum's Akhmīm sarcophagi to the late M^r Tasos Neroutsos, MD, before sending them to Athens. Neroutsos was a medical doctor living in Alexandria. He was most probably very interested in Egyptology and – as was the tendency in those years – he was self-educated on the subject. Some erroneous points in his readings and interpretations of the hieroglyphic inscriptions have been already discussed [Maravelia, Cladaki 2004, 5–20; Maravelia 2005, 7–21]. All these anthropoid sarcophagi containing the nine CT-scanned mummies are kept in the storerooms of the Museum's Egyptian Collection, along with a few more that were presented to Hellas at the beginning of the 20th Century. These coffins have never been exhibited in the past because of the lack of space in the Museum's premises (**Fig. 4 (R)**). The staff of the Egyptian Collection has recently restored the coffins. However the deficient knowledge in the maintenance of these sarcophagi, when they arrived in Hellas 135 years before, resulted in their poor condition and the splintering of some of their depictions. Regrettably parts of the inscriptions

⁹ See, for instance: [McNally 1981–1982, 26–30; Kuhlman 1983, 50 ff].

¹⁰ Personal communication.

¹¹ For 'El-Salamūni and 'El-Hawawīsh, see also: [PM IV, 17–20]; for Akhmīm, see finally: [LÄ I, 1975, 54–55: s.v. "Achmīm"].

read by Neroutsos are completely destroyed today, but due to his readings we were able to re-synthesize them to the best of our knowledge. Only one of them (**Fig. 4 (L)**) is currently on display (AIG 3340) in exhibition room № 40 [Tzachou-Alexandri 1995, 169: *pl. LX*; Cladaki-Manoli *et al.* 2002, 40–41 (see § II.21) & 56: *pl. 15a*].

The coffins are characteristic of the Early- until Mid- and Late-Ptolemaic Period relatively rich anthropoid sarcophagi, and bear the typical offering formula inscriptions and funerary liturgical spells. Chthonic gods (like Osiris, or hybrid deities like Osiris-Sokaris-Ptah) are invoked, but also heavenly and solar deities (Rē, Horakhty, Nūt, Atūm), as well as local and other gods (like Min, Horus of Behdet, Isis) are praised, in order to offer the spirit of the deceased humans rich libations of beverages and oblations of food¹². Anthropoid coffins depict the deceased with the face of a living human and the bandaged/embalmed body of a mummy. This deified hybrid entity, called *sḥ*, was considered to partake of both the divine and the human hypostases. The *sḥ*-status was achieved through a religiously correct burial, where the corpse was mummified [Shore 1992, 226–228; Germer 2000, 458–469], and provided with a mummy mask and a special coffin, in order to stride in the territory of the *horizon/lightland* (*3ḥt*) of the blessed and of incorruptibility¹³. The gilded cartonage mask placed on the face of the deceased, provided an idealistic image of him/her as eternally young and equipped with the golden skin and curled beard characteristic of a divine being (**Fig. 4 (L)**). Additionally, the correct preparation of the body and its provision with the anthropoid coffin would magically ensure the acquisition of this very blessed status. On the other hand, the presence of liturgical inscriptions, like the *offering formula* (*ḥtp-di-nsw*), or excerpts from the *Book of the Dead* (and other underworld ritual texts), could be considered as a magical funerary practice, which would be sympathetically capable of virtually creating the necessary afterlife context of victuals and provisions, thus safeguarding the immortality of the deceased humans, providing sustenance for their *spirits* (*k3w*) in the hereafter.

¹² For the cult of these deities in Panopolis and the plausible correctness of de Meulenære's assumptions, see: [de Meulenære 1988, 41–49 & *pl. VI*, especially 47].

¹³ E.g.: [*Wb.* IV, 52; *FCD*, 214–215; Schneider 1977, 65ff, *passim*].

Typologically, the sarcophagi studied here belong (more or less) to the *Swollen Type of Coffin* [Jørgensen 2001, 18]¹⁴, which is typical of the period *c.* 650 to 150 BC. This emerged during the beginning of the Saitic Dynasty and remained in use with numerous variations until the middle of the Lagid Dynasty. It was made of either wood or stone. The coffin's head was often unnaturally placed deep between the shoulders, and two decorative features, the *plinth* and the *back pillar* were practically obligatory. The deceased was depicted wearing a wig, ceremonial cosmetic lines, and frequently a symbolic chin-beard¹⁵. Finally, the mummiform body was often decorated with a broad collar, inscriptions¹⁶ and images of various divinities¹⁷. During the last three centuries BC, traditional pharaonic styles of burial were considerably and increasingly influenced by the classical motifs [Walker, Bierbrier 1997, 29]. A very elaborate nice coffin, similar to that of Lady Ta-Khered-Min (and particularly to NAM AIG 3347), characteristic of the same transitional period, is that of the priest and dignitary Hornedjitef, dating from *c.* 250 BC and found at Thebes West (°Asāsīf) [Walker, Bierbrier 1997, 29–30 & *fig. 1*]. Various coffins dating from the Late Ptolemaic and Hellenic-Roman Period, found at Akhmīm, are kept in the British Museum¹⁸. The coffins studied can be considered as representative of the final stages of development of the mid-¹⁹ and higher-status²⁰ burials of the pharaonic type, before the adoption of foreign (Hellenic and Roman) elements. All the anthropoid coffins studied in their component parts (lids, mummies,

¹⁴ For a typical example of a limestone coffin originating from Akhmīm, see: [Jørgensen 2001, 268–269].

¹⁵ On their liturgical and magical symbolism and that of other funerary embellishments and tools, see: [Jørgensen 2001, 23–28].

¹⁶ E.g.: the coffin of Petosiris at the Egyptian Museum in Cairo (J.E. 46592), bearing elaborate hieroglyphic inscriptions; see: [Lefebvre 1924, *pl. 58*]; cf also [PM IV, 174].

¹⁷ E.g.: the coffin of Nesptam'ai (ÄMB 12/66 A-B), in: [Fay 1992, 150 (№ 75)].

¹⁸ For some additional Ptolemaic coffins, see: [Berlev, Hodjash 1998, 35–36 (№ 48–50, 53, 55)].

¹⁹ See for instance NAM AIG 3341, AIG 3342, AIG 3345, and AIG 3349.

²⁰ See for instance NAM AIG 3340, AIG 3348, AIG 3343, AIG 3344, AIG 3346, and AIG 3347.

A. Maravelia, N. Bontozoglou, K. Kalogerakou, C. M. Couvaris, S. Geroulanos cartonages), as well as in the choice of decoration and inscriptions, constitute a statistically adequate and purely Egyptian assemblage. They belonged to higher and middle class persons, mainly related to the priesthood of Panopolis, who lived during the swan-song era of the ancient Egyptian Empire²¹. Finally, it is to be noted that recently the PhD Thesis of Dr Alexandra R. Klales shed ample light and a new approach to the CT study of a sample of 25 mummies from Panopolis, showing that its population was very diverse [Klales 2014].

IV. Applying Informatics in (Archaeo-)Medicine, in Order to study Ancient Egyptian Mummies

The mummies of this Research Project were examined using a multi-detector CT-Scanner (Sensation 64, Somaris 5 Software, Syngo CT2014A with ICS/IES VB42B and Windows 5.1, Build 2600: Service Pack 3, Siemens, Erlangen, Germany). Each mummy was placed on the scanner table, completely wrapped, having been safely removed from its container.

Three scans were performed for each mummy. The first one was a whole body scan, from head to toes, acquired at 120 kV and 250 mA·s with a slice thickness of 0.6 mm. An average of 5000 axial images was obtained. The second one, which covered the head only, was performed at 120 kV and 220 mA·s with a slice thickness of 1.0 mm. An average of 135 axial images was obtained. Additionally, the third one was a specific dental scan that was acquired at 120 kV and 90 mA·s with a slice thickness of 0.75 mm. An average of 190 axial images was obtained.

The axial images were initially thoroughly studied in body- and high resolution bone-algorithms, in order to examine the internal structures of the mummified bodies and to re-discover their anatomy on our Sectra Pacs Workstations. The fine anatomical details were further examined with 2-Dimensional (Multiplanar, MPR) and 3-Dimensional (Volume Rendering, VR) reconstructions, which were elaborated on the Multimodality Workstation (Multimodality Work Place, with Syngo MMWP VE40A and Syngo VE32E and Windows WinNT5.2, Service Pack 2, Siemens, Erlangen, Germany). Specific electronic measurements and calculations were made for anthropometric studies.

²¹ On this period, see: [Lloyd 2002, 395–421].

The multiplanar reconstructions involve the process of converting the data acquired from axial CT-images to coronal, sagittal or oblique 2-Dimensional images. The process proved very useful in the examination of the mummies, since some structures (usually the skeletal ones), are best studied in multiple planes. Moreover, projectional techniques, like the Maximum Intensity Projection (MIP) Images, can be used to display only the highest attenuation value from the data that is the brightest objects in the image. In our case, the osseous structures were the objects of interest which were even better visualized with thin-slaps MIPs [Dalrymple, Prasad *et al.* 2005, 1409–1428]. The 3D reconstructions were performed with the VR Technique. The Orthographic VR is an advanced 3D-Technique, which enables tissue classification, such as bone, soft tissue, air and fat, and allows for different colour assignments. This technique makes possible the external 3D-visualization of an object, bestowing different colours in different tissues. Additionally, with the Segmentation Technique, some parts of the initial image can be selectively included or excluded from the 3D image [Dalrymple, Prasad *et al.* 2005, 1409–1428]. This is usually achieved manually, using the Region-of-Interest-Editing-Method, thus allowing only for one or multiple tissues/areas of interest to be featured.

Thus, the aforementioned techniques allowed the virtual and gradual removal of the bandages and the internal, as well as the external, visualization of the mummies (**Fig. 5**), virtually bringing them back to life, more than 2000 years after they passed away, proving once more the fruitful interdisciplinary collaboration between Informatics, Medicine, Palaeopathology and Archaeology. For some aspects of the CT-Scanner described above and from various phases of the scanning, see the relevant pictures (**Fig. 2–3, 14**).

V. Select Preliminary Results and Case-Studies of our Project

In this Section we present selected preliminary results for some of the scanned mummies, in order to demonstrate how the interdisciplinary interaction between the application of SI methods (cf. Section IV, *supra*) assists us in examining the scanned mummies and obtaining useful conclusions concerning their situation, possible cause(s) of death, various illnesses or syndromes that those ancient individuals might have, the state of their teeth, and other pathologies. We point

out that in all five mummies examined until now with Computed Tomography we could not detect a possible cause of death; for some of them there were some pathological reasons, but no certainty as to which one was the real cause of their death.

V.1. The Case of the Mummy of Sekhem (AIG 3343). This mummy (**Fig. 4 (R)**) belonged to a young male with an estimated age between 20–30 years old (*Shm*), his father being Ta-Khor (*T3-Hr*) [Maravelia 2005, 8–9, 12 & fig. 1a, 15 & fig. 2b]²². This is the case of a short young adult with a (cadaveric) height of 1.48 m (\pm 5 cm) and its preservation is excellent (the best of all mummies, out of the five scanned so far). The CT-Scanning revealed several interesting findings, like the remnants of some organs in the thoracic cavity, with a barely discernible heart and mild hypertrophic distortions of the higher thoracic spine, as well as the transnasal excerebration of this ancient individual, from both nostrils, where small packages were placed; the cribriform plate is broken and the anterior clinoid is also broken from the left side, still in existence but fallen in the resin (with an optical density of \sim 140 HU) applied during mummification, this last being detected in the back of the skull, as well as all around the vertebral column. The cranium is thinner than that of an ordinary contemporary male adult. There are also remnants of his eyes and the optical nerves left in the eye-orbits, while in the neck dolichoectasia of the spinal arteries was detected, together with degeneration of the temporalmandibular joint. The acoustic ossicles and the labyrinth are also very well preserved. We also detected a package with the mummified viscera of the deceased in front of the abdominal cavity and a small amorphous formation (bone or amulet). The former are most probably the liver, the intestines, the stomach and the lungs, and perhaps also a kidney, prepared (as was the funerary custom) in special canopic packs. Further careful observation showed extensive wear in the teeth of this individual (**Fig. 6**): not only adamantine loss has been observed

²² In that paper there was a misprint due to the erroneous transposition of the names and inscriptions of AIG 3343 to AIG 3344 and vice versa! Actually, the description and inscriptions of p. 8 for AIG 3343 must be meant for AIG 3344 and vice versa; same for the pictures and inscriptions in pp. 12–13 (meant for AIG 3344) and in pp. 14–15 (meant for 3343)! Additionally, the very last sentence of n. 14 (in p. 9) must be deleted! On these names, see e.g.: [Ranke 1952, II, 317, 3; 327, 8–9].

in this mummy, but also the absence of the 1st molar in both left and right sides; we also detected a rather unique find related to his teeth, which is currently under publication [Pantazis, Kyriazi, Maravelia *et al.* 2020, *in press*]. In the abdomen we found that transperineal evisceration was performed before mummifying this individual (**Fig. 7**) (characteristic of the area of Panopolis), remnants of some organs and a canopic package in the abdominal cavity (**Fig. 5 (LR)**), as well as remnants of his penis (**Fig. 7**), which is proof of the sex of this ancient individual²³, as well as the form of his supra-orbital ridges, in agreement with the inscriptions on the coffin, which are barely visible today. As for his musculoskeletal system, the ligaments are very prominent. Furthermore, between the 4th and the 5th vertebrae there is a stenosis and also a degeneration (osteophytes), an idiopathic case, resulting from a strong inflammation that would have created strong pain in this ancient individual for at least ~ 1 year, until later it was “frozen”; this is currently under publication. If more degenerative traces like this were detected (which is not the case), one could probably think that this person could have been a labourer, a probability that must definitely be ruled out, because of the excellent mummification technique and the rather elaborate inscribed (although moderately preserved) coffin [Maravelia 2005, 8–9, 12], suggesting that Sekhem was a member of the higher societal *strata* of Ptolemaic Panopolis, related to the local priesthood, as is also the case for the rest of the mummies of our sample (**Fig. 4 (R)**). Additionally, we have detected a possible Marfan Syndrome (cf. [Panzer, Thompson *et al.* 2018, 78–85]), which would also have made Sekhem to suffer from pain due to nerve pressure, also currently under publication. No other serious degenerative changes were detected and the tongue was well preserved. Furthermore, inside the bandages of the lower left side of the neck, an amorphous formation (a bone or an amulet) was detected ($D_{max} = 1.7$ cm, $W_{max} = 0.5$ cm). Finally we note that the measured width of the linen bandages used was ~ 4 cm to 5 cm, this mummy being the most well embalmed of all the other scanned ones, and that the knees of Sekhem provide a glimpse on nice anatomical elements, without any pathological findings.

²³ According to CT VI, 576: §§ 191a–191p, the deceased man keeps his phallus *post mortem*, in order to be able to enjoy copulation and to beget his offspring (cf. too [Colazilli 2017, 280–282]).

V.2. The Case of the Mummy of Ta-di-thed-Amūn (AIG 3346).

This mummy belonged to a male (*T3-di-td-Imn*) of approximately 20 years old, his father being Onnoupbris (*Wnn-nfr*) and his mother S^cankh (*S^cnh*) [Maravelia 2005, 9, 16–17 & fig. 3a–3b]²⁴, with a (cadaveric) height of 1.45 m. The CT-Scanning revealed wear in the pelvis and a *post mortem* dislocation of the pelvic bones. From the careful study of the results of the CT-Scanning for this mummy, one unexpected conclusion was deduced: this ancient Egyptian individual was suffering from a rare syndrome, discussed in another paper [Michailidis, Kyriazi, Maravelia *et al.* 2019, 1165–1169], a fact proven by our unusual finding concerning the skull; that situation and the possible social implications in this person's life are thoroughly discussed in our paper [Michailidis, Kyriazi, Maravelia *et. al* 2019, 1167–1168]. There is extensive literature on studies of Egyptian mummies reporting in great detail the embalming methods used and many different probable pathologies and injuries [Cockburn, Cockburn 2006]; however, there are very few reports of pathological findings of the nasal cavities [Illner *et al.* 2002, 503–506; Hagedorn *et al.* 2002, 71; Marquez *et al.* 2015, 1072–1084; Pahor 1992, 773–779], as is the unexpected condition uncovered for this mummy (SS-Syndrome), using interdisciplinary medical and Informatics' methods. A cyst was also detected in the right 3rd molar of this mummy and the tongue was well-preserved.

The study of this mummy revealed more interesting facts, for instance the embalming technique and abundant bandages used, as well as the heart that was left inside the thoracic cavity of this ancient individual, after being separately embalmed (**Fig. 8**), following the ancient Egyptian funerary customs. Additionally, we uncovered remnants of a faience-bead network, covering the mummy on both the head (**Fig. 9**) and the body, which is today almost fully lost²⁵. On the other hand, the teeth of the mummy showed adamantine wear. The evisceration of this individual took place through a transperineal trespass (hinting to the local funerary customs) and there are remnants of

²⁴ On these names, see e.g.: [Ranke 1952, II, 328, 12–13; Ranke 1935, I, 79, 19–20].

²⁵ On such bead-net shrouds, used from the TIP onwards and placed on the outer wrappings of both male and female mummies, cf. e.g.: [Friedman 1998, 160, № 163–164; 249].

muscles in the abdominal cavity. More details will be given and thoroughly discussed later on in new papers, as well as in our integrated work, which will be published in a few years by Archaeopress (*Egyptology Series*) in Oxford. There was no evidence of brain removal, the brain remnants having shrunk and sunk inside the cranial cavity (**Fig. 10–11**) and we have observed that the ethmoid cells and the cribriform plate were intact [Michailidis, Kyriazi, Maravelia *et al.* 2019, 1166], a fact meaning that there was no attempt of transnasal excerebration during the mummification of this particular individual, which was a very common practice in many ancient Egyptian mummies [Fanous, Couldwell 2012, 743–748; Cockburn *et al.* 2006, 21]. According to the funerary and religious beliefs of the Egyptians, the heart (**Fig. 8**; the brain was just disposed of) was the most important constituent of humans and was to be judged in the hereafter in front of Osiris.

V.3. The Case of the Mummy of Ta-khered-Min (AIG 3348).

Since we have not yet published forensically and medically this interesting mummy (**Fig. 14–15**), our preliminary study here will be more extensive than for the previous two. Ta-khered-Min (*T3-hrd-Mnw*) was a Ritual Dancer of Min (*Thbt nt Mnw*), the daughter of a prominent family of the local priesthood of Panopolis. Her father (*Trt-Hr-r-w* / *Ἱρτοχάρης*) was the High-Priest of the solar god Horakhty and the 4th Prophet of Min and her mother (*Tst-nḥbwt* / *Ἰσττωνήβη*) was a respected noble lady (*nbt-pr*)²⁶. Her mummy was dated to the Early Ptolemaic Period (c. 304–200 BC), and it is egyptologically the most fascinating of them, since she belonged to the higher societal layers [Maravelia, Cladaki 2004, 8–9, 19–20 & *fig. 5a–5b*]. This mummy, however, presented us with unexpected findings, being rather abnormal in the relative disorder of its component parts, especially the bones (**Fig. 15**).

The mummy belonged to a female with an estimated age of 20–30 years and a stature of 1.51 m. However, the CT-Scanning revealed that the body was badly preserved with severe damage of the structures of the torso. In the head there is evidence of a failed attempt of

²⁶ On these names, see e.g.: [Maravelia, Cladaki 2004, 9, *nn* 36, 38; Ranke 1952, II, 328, 12–13].

transnasal excerebration, while a wooden stick is supporting it (**Fig. 12–13**). Two small packs are placed within the orbits and there is a foreign radio-opaque body in the left. Wooden implants have been used to create a nose substitute, thus reconstructing it in an attempt of ancient plastic surgery. In the thorax and abdomen there is significant and irregular disruption, while multiple vertebrae are missing and many existing vertebrae are disarticulated. Non-healed multiple rib-fractures are also present. Regarding the appendicular skeleton the structures of both upper and lower limbs remain very well preserved. However, the overall condition of the body reveals disruption and decay, as if the mummification was delayed for some intriguing reason(s)! Why was this so? Using interdisciplinary methods based on Medicine, Forensics and Egyptology, we are currently trying to resolve these unexpected puzzles...

This is the only one of the five scanned until now with hands crossed, intriguingly featuring the poorest mummification of all the other four (**Fig. 14**). This fact is by itself strange indeed, since the priestess belonged to the higher societal *strata*. Its height is $1.51 \text{ m} \pm 5 \text{ cm}$ (the cadaveric height [White, Folkens 2005, 398]). We have detected many visible layers of resin between the mummification bandages (which are fewer and not tightly wrapped, with more resin between), which differs from the other scanned mummies. The skull appears female so the mummy is most probably that of a female, in accordance with the inscriptions on the coffin. The pelvis is damaged and broken. An age estimate could be perhaps 25–30 years, thus the mummy belongs to a young adult. The teeth are better preserved than those of some other examined mummies, with no periodontitis, but with adamantine wear. Due to the existing upper left 3rd molar, the age is assuredly > 20 years, in agreement with the aforementioned estimate. A piece of cylindrical wood (40 cm of length and 1.3 cm in diameter) has been placed inside the head through the foramen magnum and parallel to where the vertebral column would be (**Fig. 12–13**), most probably to support the head. It is covered with bandages of linen. Transnasal excerebration was tried, but the wooden tool has not entered the brain cavity, which implies that the embalmer tried to enter but stopped. Some parts of the brain remained shrunken at the occipital bottom part of the skull, because the mummy was lying in a supine position (**Fig. 12–13**). Nasal entering took place first, then

(maybe because of a clumsy movement of one or more of the embalmers that damaged the corpse?) the placement of the supportive wood took place. The eyes of the corpse are missing, but in one of the orbits there are remnants of bones and two packages (maybe the embalmed eyes?), though most probably it is just linen pieces. The vertebral column from the lumbar vertebrae to the head is highly deformed, scattered around inside the mummy and damaged, while there are missing vertebrae and fractures of ribs without porosis. However, the hands and legs are intact and complete. This does not look like a *pre mortem* injury or similar. There is no thoracic cavity as in other cases. The (biggest number of) bones that would form the thoracic cavity are heavily displaced and scattered/thrown inside the mummy in an approximation of the proper anatomy. There are some cervical and thoracic vertebrae thrown in (the two scapulae and ribs), as if there was not enough space in the sarcophagus and one had to place the big mummy “squeezed” and broken on purpose and haphazardly. The pelvic girdle is also present, though in a compressed, broken and deformed state. This could be the result of the actions of the embalmers, after the mummification was completed, in order to “fit” the mummy into a smaller coffin, thus avoiding more costly expenses to prepare a new coffin with the correct dimensions (see e.g.: [Gray 1966, 138; Gray 1973, 52; Salter-Pedersen 2004, 17–18]).

Maybe the dead body was left and started to decompose for some days. The major part of the decomposition would take place in the abdomen, the thorax and the head and less so in the limbs. Afterwards it would be easier to remove the liquefied brain from the separated skull and the organs through the perineum. It would also be easier to compress and fracture the thorax, abdomen and the pelvis so they could fit in a smaller sarcophagus. Could this decomposition have been intentional (the dead body would be left to decompose on purpose?), or perhaps the dead body was not discovered in time and was found decomposing some days after the death of the priestess? The dry Egyptian climate would ensure that the limbs would be naturally mummified. We think that there is no possibility of injury, but most probably rather putrefaction (the body was left or found some days after death?) or perhaps even the possibility of a second re-burial (and a re-trial of embalmment?), a long time after the initial burial. Another important finding is the “cosmetic operation”, in order to reconstruct

her nose! The embalmers put two pieces of wood and a piece made of different material, to recreate the nose. But why? Maybe because of an error during the transnasal removal of the brain, that remained inchoate and incomplete (see *supra*). Or, perhaps, because putrefaction had already altered the nose? The missing eyes perhaps suggest the latter too. Most possibly, however, there are three explanations for the above findings, which might be separately or perhaps simultaneously applicable in her case (maybe 2 with 3, although 1 seems the most plausible): **1.** The body of the (relatively young) priestess was left on purpose to decompose, to avoid any probable necrophilia mistreatment of her corpse by the male embalmers²⁷. **2.** She was murdered during one of the revolts of the local Egyptian princes against the Ptolemies (perhaps *Hr-Wnn-Nfr*: 205–199 BC or *ʿnh-Wnn-Nfr*: 199–186 BC), maybe during some riots, and her body was found later²⁸. **3.** She was the victim of an epidemic and her body was embalmed some time after her death, but not immediately, due to the social disorder that would have occurred after this pestilence, because for some unknown reasons the corpse was not found early enough²⁹. However,

²⁷ Cf. e.g.: Hērodotos II, 89, 1–2: “Τὰς δὲ γυναῖκας τῶν ἐπιφανέων ἀνδρῶν, ἐπεὰν τελευτήσωσι, οὐ παραντίκα διδοῦσι ταριχεύειν, οὐδὲ ὅσαι ἂν ἔωσι εὐειδέες κάρτα καὶ λόγου πλεῦνος γυναῖκες· ἀλλ’ ἐπεὰν τριταῖαι ἢ τεταρταῖαι γένωνται, οὕτω παραδιδούσι τοῖσι ταριχεύουσι. Τοῦτο δὲ ποιεῦσι οὕτω τοῦδε εἵνεκεν, ἵνα μὴ σφι οἱ ταριχευταὶ μίσγωνται τῇσι γυναίξιν. Λαμφθῆναι γάρ τινά φασι μισγόμενον νεκρῷ προσφάτῳ γυναικός, κατεῖπαι δὲ τὸν ὁμότεχνον”, explicitly stating that in the case of beautiful young women the bodies were handled to the embalmers 3–4 days after their death. Perhaps the facial reconstruction of this mummy could provide a hint on this reason, depending on her beauty. According to two scholars [d’Auria 1988, 18; Fleming *et al.* 1980, 50]: “during the Ptolemaic and Roman Periods, the poor quality of mummification and the fact that the bodies were in an advanced state of decomposition before they were embalmed often resulted in many of the bones being dislocated” (see too [Salter-Pedersen 2004, 17–18]).

²⁸ On these revolts, see: [Veisse 2004, 78–79; Hölbl 2001, 154–156]; let it be noted that, according to a certain Demotic source, a siege in Abydos, nearby Panopolis, took place in August 199 BC by the Ptolemaic troops [Hölbl 2001, 155], which might provide a plausible date for the death of Takhered-Min, should this assumption be correct.

²⁹ On epidemics in Ptolemaic Egypt, see: [Lang 2012, 10, n. 30; 11, n. 36; 12–13, n. 43; 18].

in most cases of epidemic diseases it is rather difficult to detect their imprints on a mummified body through CT, especially when the individual afflicted died in the first day of his/her contamination. Our further results are currently being evaluated and will be published separately in the immediate future. Finally, we note that the organs were removed through the perineum, as was the case in Akhmīm, and no section on the body was detected.

Consequently, before our study (which is currently in full progress, with the use of more interdisciplinary methods) proceeds, we shall not endeavour to explain all the above fully and simultaneously. Our further results are currently being evaluated and will be published separately in the immediate future.

VI. Results and Discussion

We have presented some unexpected and interesting findings in mummies dating from the Ptolemaic Period and originating from excavations at Panopolis, examined with Computed Tomography for the first time in Greece. We have described the fruitful interaction between Medical Archaeology and Informatics (see Sections II, IV, *supra*), namely the application of Smart Informatics (Smart Computing) and their methods [Maravelia 2017, 11–20; Pawlak 1991; Waterman 1986; for Artificial Intelligence see: Brož, Dostál 2012; Combi 1989–2019; Luger 2005; Bodenreider, Burgun 2005], in order to perform our study and to process the raw results, reconstructing non-invasively the morphology and anatomy of these mummies belonging to ancient Egyptian individuals of both sexes, a fact which revealed extremely important and in some cases rare and unexpected conditions. The above pictures (**Fig. 3, 5–15**) are a proof that interdisciplinarity is functional and fruitful indeed in the case of Palaeopathology, Forensics, Egyptology and Informatics³⁰.

Based on the aforementioned interdisciplinary study, we have studied the age and the sex of the mummies in comparison to the inscriptions found on their sarcophagi, we have examined the mummification methods and the concomitant alterations related to the preparation of these bodies for burial, and we have comparatively revealed the damages that these mummies suffered *post mortem* during the

³⁰ Cf. too: [Maravelia 2017, 11–20].

centuries elapsed since their death. Furthermore, we have uncovered illnesses and syndromes from which these ancient individuals were suffering during their lifetimes, as well as information related to their dietary habits (based e.g.: on their teeth-wear, partially due to the specific ways the food was prepared, & c.). Interesting findings (except those unexpected and particularly intriguing that are discussed elsewhere), are those concerning the excerebration, the evisceration and the attempts to conserve the “holy” internal organs (heart, lungs, stomach, liver and intestines), the attempt to conserve the form of the once living body (*ht*), by mummifying the corpse (*h3t*), thus transforming it into a virtually divine “ennobled body” (*s^ch*), as well as the comparative study of the embalment techniques and materials (e.g.: bandages and their characteristics, other materials like wood, funerary implements, & c.). We have also uncovered proofs of medical interventions [Forshaw 2009a, 421–424; Forshaw 2009b, 481–486; Wade *et al.* 2012, 217–222], like e.g.: a case of invasive dentistry in one of the mummies, which is currently under publication in another paper [Pantazis, Kyriazi, Maravelia *et al.* 2020, *in press*]. Using SI techniques and advanced software, we mapped our most important findings in either 2D or spectacular 3D images, some selected of them presented above, and many more of them being under publication.

VII. Conclusions and Future Work

As is evident from the above, the use of SI in the case of Archaeo-Medicine is another proof of the successful application of Informatics in both Medicine and Archaeology (viz.: Egyptology that offers the unique possibility to Scientists and Egyptologists to look face-to-face with the extremely well-preserved bodies that were embalmed some thousands of years ago³¹, keeping inside them important “secrets” of Medicine, Epidemiology, Dentistry and Forensics), providing significant and sometimes surprisingly unexpected and unique results³². Hence, we have shown the effective and extremely fruitful collaboration between Egyptology, Archaeo-Medicine and

³¹ Cf.: [Partridge 1994].

³² See e.g.: [Kalampoukas, Kyriazi, Maravelia *et al.* 2020, *in press*; cf.: Jackowski *et al.* 2008, 1477–1492].

Smart Informatics, where the application of combined methods has been tested with excellent results, revealing medical situations that are rare, thus not only helping the interdisciplinarity between different Sciences, but also providing new future insights into the comparative study between modern and ancient cases of patients³³. We firmly believe that future studies similar to our current work will pave the way towards the comparative analysis between ancient and modern medical cases of patients, as well as foster an even more inventive and innovative application of SI to modern Medicine and Medical Archaeology.

Acknowledgments

The authors of this paper, are highly indebted to all the aforementioned Members of our Team for their participation in the Mummy Project and we should like to thank them for their collaboration. We should also like to thank the CEO of the AMC, M^r **Georgios Apostolopoulos**, the General Financial Director (CFO) of AMC, M^r **Emmanuel Markopoulos** and his Team, as well as the Director for Public Relations of AMC, M^r **Kostis Chatzigiannakis**, and his Team, for their funding, warm collaboration and assistance, which made this Project feasible! The funding of the transportation of the mummies to and from the AMC to the NAM has been generously provided by the special Transporting Company Orphée Beinoglou and the AMC, a fact for which we feel very grateful. The Director (Dr **Maria Lagogi-anni**) and the Staff of the NAM are also hereby kindly acknowledged for their assistance. The protective role and assistance of the Hellenic Secret Police during the transportation and scanning of the mummies is also to be kindly acknowledged. Finally, we should like to thank two anonymous referees for some useful comments, which improved our paper, as well as Egyptologist Dr **Pauline Norris** (UK), who critically read our paper and made it more idiomatic in English. Last but not least, Dr **Mykola Tarasenko** must be kindly acknowledged for having edited our text following the editorial guidelines of *The Oriental Studies*.

³³ See: [Cockburn *et al.* 2006; Coiera 2015; Salem 2007, 9–13; Salem, Voskoglou 2013, 68–77; Salem, Katoua 2012, 516–522]; cf. too: [Aitken 1990].

Illustrations



Fig. 1. Part of the Team of the *Mummy Project* (from left to right): Dr Nikolaos Bontozoglou, MD; Prof. Dr Alicia Maravelia; M^{rs} Helen Tourna; M^r Emmanuel Markopoulos; M^r Kostis Chatzigiannakis; Em. Prof. Dr Stephanos Geroulanos, MD; M^r Panaghiotis Lazaris; and M^r Constantinos Couvaris, MD. Premises of the Egyptian Collection of NAM, in front of the coffin of Hapy, Wednesday 2nd October 2013. © Copyright & Courtesy of the Hellenic Institute of Egyptology, Athens, Hellas, 2013.



Fig. 2. Prof. Dr Alicia Maravelia, between Dr Nikolaos Bontozoglou, MD, Head of the CT-Unit (right) and M^r Emmanuel Markopoulos, Gen. Financial Director of AMC (left) on Saturday 22nd October 2016. © Copyright & Courtesy of the Hellenic Institute of Egyptology, Athens, Hellas, 2016.

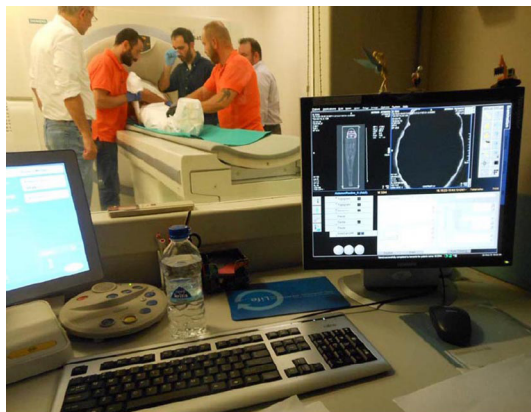


Fig. 3. Members of the Research Team of the Mummy Project and technicians at work, during the first part of the scanning (Saturday 22nd October 2016). Dr Nikolaos Bontozoglou, MD, Head of the CT-Unit (left, with white shirt) and Mr Panagiotis Lazaris, Conservator of the Egyptian Collection of NAM (right, with blue shirt), handling a mummy. View from the control-cockpit of the CT-Unit of the AMC. © Copyright & Courtesy of the Hellenic Institute of Egyptology, Athens, Hellas, 2016.



Fig. 4. On the left, the wooden anthropoid coffin belonging to Hapy (AIG 3340), featuring its interior with the mummy, wearing a funerary mask and cartonage implements (left), and its lid (right), where the partly obliterated column-inscription is visible, as well as a curled beard. On the right, the coffin of Sekhem (AIG 3343), with barely discernible hieroglyphic inscription. © Copyright & Courtesy of the National Archaeological Museum, Athens, Hellas, 2004–2005, 2019.

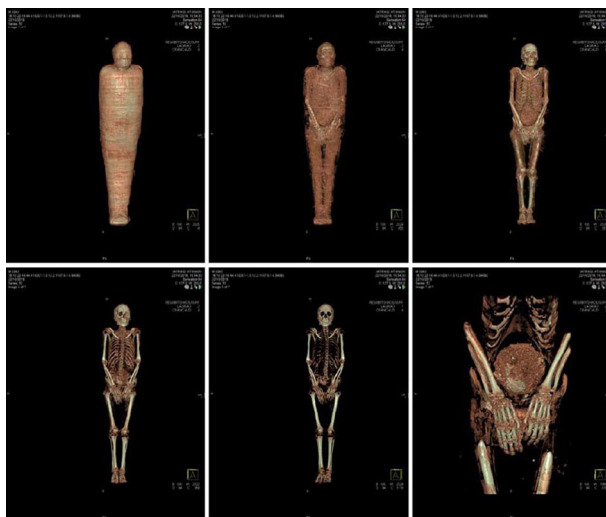
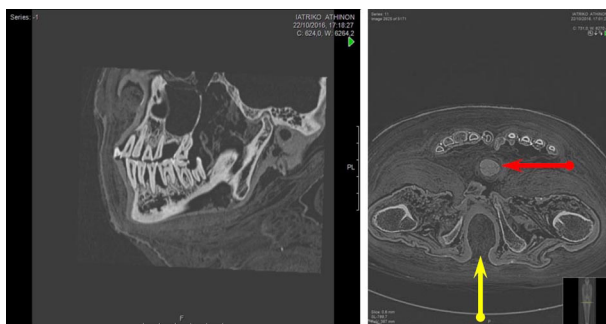


Fig. 5. The gradual virtual removal of linen wrappings for the mummy AIG 3343 is here visible, as well as the details it uncovers. The last detail-photo (lower right) reveals the placement of the separately mummified viscera packed in front of the abdomen, as was the case several times during mummification. © Copyright & Courtesy of the Athens Medical Centre, Athens, Hellas, 2016–2019.



Figures 6–7. On the left, lateral projection of the teeth of mummy AIG 3343 showing extensive dental wear. On the right, the transperineal trespass for the evisceration is visible (yellow arrow), as well as the remnants of the penis (red arrow); on the same picture the embalmmnt technique and the bandages used tightly are also visible, revealing a good and professional mummification work (the best of all other scanned corpses). © Copyright & Courtesy of the Athens Medical Centre, Athens, Hellas, 2016–2019.

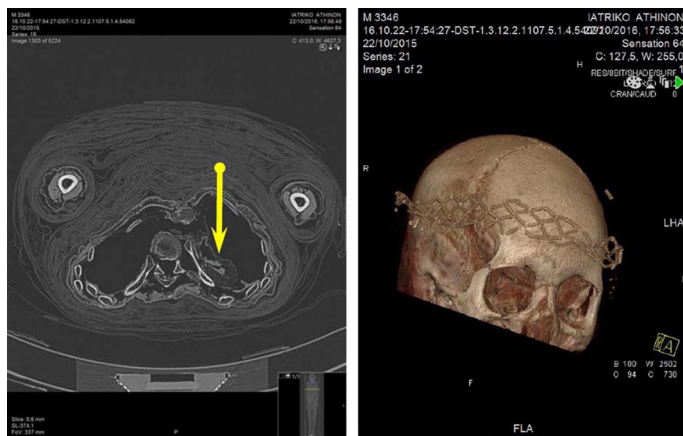


Fig. 8–9. On the left, the embalming technique and bandages of mummy AIG 3346 are revealed, featuring the separately embalmed remnants of the heart (yellow arrow) inside the thoracic cavity of this ancient individual. On the right, magnified aspect of the upper cranium, showing the remnants of a faience-bead shroud used as a funerary implement during mummification. Some more beads were found on the body. © Copyright & Courtesy of the Athens Medical Centre, Athens, Hellas, 2016–2019.

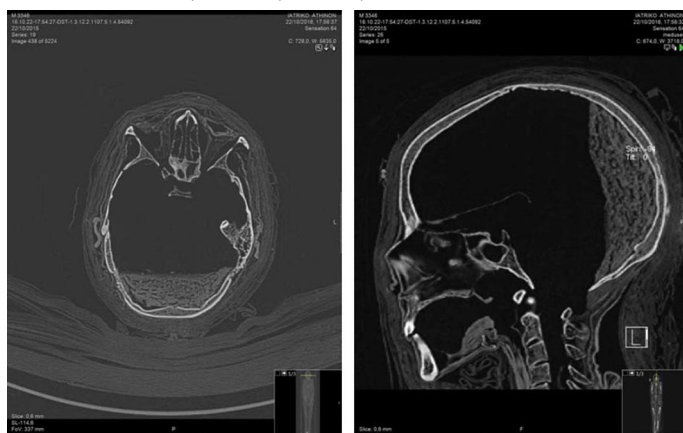


Fig. 10–11. On the left, aspect of the cranium of the mummy AIG 3346, revealing the remnants of the brain and the intact ethmoid cells. On the right, lateral projection of the same characteristic findings, showing the shrinkage of the brain and its sinking because of the supine position of the mummy. © Copyright & Courtesy of the Athens Medical Centre, Athens, Hellas, 2016–2019.

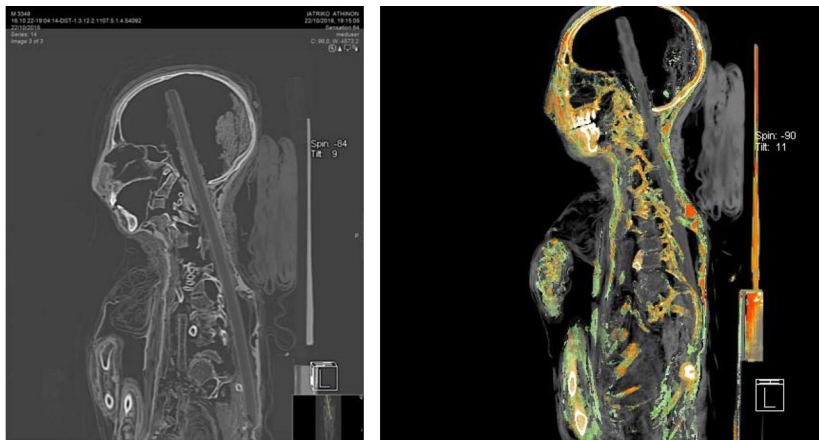


Fig. 12–13. On the left, lateral aspect of the upper part of the body and cranium of the mummy AIG 3348, revealing the remnants of the brain and the intact cribriform plate. On the right, same with pseudo-colours, to reveal details: the insertion of a long piece of wood to support the mummy-head is clearly visible, as well as her brain remnants shrunken at the occipital bottom part of the skull. © Copyright & Courtesy of the Athens Medical Centre, Athens, Hellas, 2016–2019.



Fig. 14. Aspect from the scanning of the mummy AIG 3348, featuring abnormal protuberances of the wrappings, as well as an unusual displacement of the head, due to the supporting wood. The “prosthetic” or “cosmetic” nose is also clearly visible, protruding under the linen shroud on the covered face. © Copyright & Courtesy of the Hellenic Institute of Egyptology, Athens, Hellas, 2016.

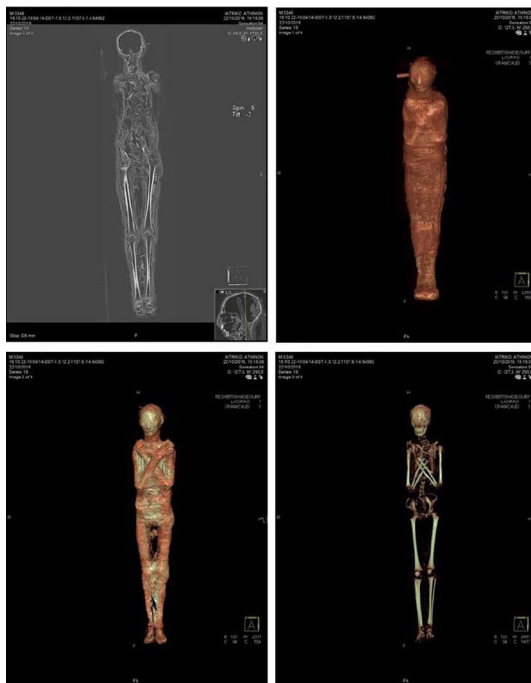


Fig. 15. The gradual virtual unwrapping of the linen bandages for the mummy AIG 3348 is here shown, as well as the details it uncovers. The first b/w photo (upper left) reveals the whole-body configuration of the mummy (from the back side), proving the disordered placement of bones in the thoracic cavity, as well as in the upper abdomen; cf. also the last photo (lower right), featuring the X-crossed hands of this particular mummy (opposite to the posture of all the other scanned ones), symbolizing her identification to Osiris (let us not forget that she was a priestess). The poorer wrapping of the corpse (compared e.g.: to that of 3343) is clearly visible (see **Fig.15** (UR & LL) and **Fig. 5** (UL & UC)). © Copyright & Courtesy of the Athens Medical Centre, Athens, Hellas, 2016–2019.

LIST OF ABBREVIATIONS

BMD = Shaw I. and Nicholson P. (eds) (1996), *British Museum Dictionary of Ancient Egypt*, AUC Press, London.

EG = Gardiner A. H. (1988), *Egyptian Grammar: Being an Introduction to the Study of Hieroglyphs*, 3rd Ed., Griffith Institute, Ashmolean Museum, Oxford.

FCD = Faulkner R. O. (1991), *A Concise Dictionary of Middle Egyptian*, Griffith Institute, Oxford.

A. Maravelia, N. Bontozoglou, K. Kalogerakou, C. M. Couvaris, S. Geroulanos

LÄ = Helck W. and Otto E. (eds.) (1975–1989), *Lexikon der Ägyptologie*, Bd. I–VII, Harrassowitz, Wiesbaden.

ΠΑΕ – *Πρακτικά Αρχαιολογικῆς Ἑταιρείας* (1884), Ἀθήναι.

PM = Porter B. and Moss R. L. B. (1939–1988), *Topographical Bibliography of Ancient Egyptian Hieroglyphic Texts, Reliefs and Paintings*, Vol. I–VIII, Griffith Institute, Oxford.

SGL – *SGL News Release* (2004), California and London.

Wb. = Erman A. and Grapow H. (eds.) (1926–1931), *Wörterbuch der ägyptischen Sprache*, Bd. I–V, J. Hinrichs, Leipzig.

REFERENCES

Aitken M. J. (1990), *Science-Based Dating in Archaeology*, Longman, London.

Aufderheide C., Zlonis M. Cartmell L. L., Zimmerman M. R., Sheldrick P., Cook M., and Molto J. E. (1999), “Human Mummification Practices at Ismant ‘El-Kharab”, *The Journal of Egyptian Archaeology*, Vol. 85, pp. 197–210.

Berlev O. and Hodjash S. (1998), *Catalogue of the Monuments of Ancient Egypt from the Museums of the Russian Federation, Ukraine, Bielorrussia, Caucasus, Middle Asia and the Baltic States*, Orbis Biblicus et Orientalis, Vol. 17, University Press Freiburg / Vandenhoeck & Ruprecht Göttingen, Freiburg and Göttingen.

Bodenreider O. and Burgun A. (2005), *Biomedical Ontologies, Medical Informatics: Advances in Knowledge Management and Data Mining in Biomedicine*, Springer-Verlag, Berlin.

Browarski E. J. (1985), “Akhmim in the Old Kingdom and First Intermediate Period”, P. Posener-Krieger (ed.), *Mélanges Gamal Ed-din Mokhtar*, Vol. 1, IFAO / Diffusion SEVPO, Cairo and Paris.

Brož Z. and Dostál P. (2012), *Multilingual Dictionary of Artificial Intelligence*, CERM Academic Publishing House, Brno.

Chan S. S., Elias J. P., Hysell M. E., and Hallowell M. J. (2008), “CT of a Ptolemaic Period Mummy from the Ancient Egyptian City of Akhmim”, *RadioGraphics*, Vol. 28 (7), pp. 2023–32.

Cladaki-Manoli E. *et al.* (2002), “Egyptian Thesauri in the National Archaeological Museum of Athens: § II.21. Anthropoid Inner Coffin of a Man with Mummy”, A.-A. Maravelia (ed.), *Ancient Egypt and Antique Europe: Two Parts of the Mediterranean World. Papers from a Session held at the 7th Annual Meeting of the EAA in Esslingen 2001*, BAR International Series 1052, Archaeopress, Oxford, pp. 31–56.

Cockburn A., Cockburn E., and Reyman T. A. (2006), *Mummies, Disease and Ancient Cultures*, Cambridge University Press, Cambridge.

Coiera E. (2015), *Guide to Health Informatics*, CRC Press, Boca Raton FL.

Colazilli A. (2017), "The Sexual Identity of Mummies and their Sexuality in the Hereafter: Body Restoration, Ritual and Religious Belief", K.-A. Kóthay (ed.), *Burial and Mortuary Practices in Late Period and Graeco-Roman Egypt: Proceedings of the International Conference held at the Museum of Fine Arts. Budapest, 17–19 July 2014*, Museum of Fine Arts, Budapest, pp. 277–84 and pl. 1–3.

Combi C. (ed.) (1989–2019), *Artificial Intelligence in Medicine*, Nos. 1–94, Elsevier, Amsterdam.

Cramer L., Brix A., Matin E., Rühli F., and Hussein K. (2018), "Computed Tomography-Detected Palaeopathologies in Ancient Egyptian Mummies", *Current Problems in Diagnostic Radiology*, No. 47 (4), pp. 225–32.

Dalrymple N. C., Prasad S. R., Freckleton M. W., and Chintapalli K. N. (2005), "Informatics in Radiology (InfoRAD): Introduction to the Language of Three-Dimensional Imaging with Multidetector CT", *Radiographics*, No. 25 (5), pp. 1409–28.

D'Auria S. (1988), "Mummification in Ancient Egypt", S. d'Auria et al. (eds.), *Mummies and Magic: The Funerary Arts of Ancient Egypt*, Museum of Fine Arts, Boston, pp. 14–9.

David A. R. (1990), *The Manchester Mummy Project*, Manchester Museum, Manchester.

de Meulenære H. (1988), "Prophètes et danseurs Panopolitains à la Basse Époque", *Bulletin de l'Institut Français d'Archéologie Orientale*, T. 88, pp. 41–9 and pl. VI.

Fanous A. A. and Couldwell W. T. (2012), "Transnasal Excerebration Surgery in Ancient Egypt", *J. Neurosurg*, No. 116, pp. 743–8.

Fay B. (1992), *Egyptian Museum Berlin*, 5th Ed., SMPK, Berlin.

Fleming S. J., Fishman B., O'Connor D., and Silverman D. (1980), *The Egyptian Mummy Secrets and Science*, The University Museum and University of Philadelphia, Philadelphia.

Forshaw R. J. (2009a), "Dental Health and Disease in Ancient Egypt", *British Dental Journal*, Vol. 206 (8), pp. 421–4.

Forshaw R. J. (2009b), "The Practice of Dentistry in Ancient Egypt", *British Dental Journal*, Vol. 206 (9), 2009b, pp. 481–6.

A. Maravelia, N. Bontozoglou, K. Kalogerakou, C. M. Couvaris, S. Geroulanos

Friedman F. D. (ed.) (1998), *Gifts of the Nile: Ancient Egyptian Faience*, Thames and Hudson, London.

Germer R. (1991), *Mumien: Zeugen des Pharaonenreiches*, Artemis und Winkler, Zürich and München.

Germer R. (2000), "La momification", R. Schulz and M. Seidel (eds.), *L'Égypte: Sur les traces de la civilisation pharaonique*, Köne-mann, Cologne, pp. 458–69.

Gray P. H. K. (1966), "Embalmer's Restorations", *The Journal of Egyptian Archaeology*, Vol. 52, pp. 138–40.

Gray P. H. K. (1973), "The Radiography of Mummies of Ancient Egyptians D. R. Brothwell and B. A. Chiarelli (eds.), *Population Biology of the Ancient Egyptians*, Academic Press, London, pp. 51–3.

Guilhou N. and Perraud A. (2010), *Le sarcophage du Muséum d'Histoire Naturelle de Perpignan: La momie de Iouefenkhsou (Jw=f-n-Hnsw). Entreprise collective menée par les membres de l'Association "Les Amis de l'Égypte Ancienne"*, AAÉA, Saint-Estève.

Hagedorn H., Zink A., and Nerlich A. (2002), "Endoscopic Examinations of the Paranasal Sinuses and the Middle Ear in Ancient Egyptian Mummies", *Abstracts Book of the 14th European Meeting of the Palaeopathology Association*, University of Coimbra, Coimbra, p. 71.

Hannig R. (2000), *Großes Handwörterbuch Deutsch–Ägyptisch (2800–950 v. Chr.)*, Philipp von Zabern, Mainz.

Hannig R. (2009), *Großes Handwörterbuch Ägyptisch–Deutsch (2800–950 v. Chr.)*, 5th Ed., Philipp von Zabern, Mainz.

Harris J. R. and Wente E. F. (1980), *An X-Ray Atlas of the Royal Mummies*, University of Chicago Press, Chicago.

Hart G. (1987), *A Dictionary of Egyptian Gods and Goddesses*, Routledge & Kegan Paul, London.

Hölbl G. (2001), *A History of the Ptolemaic Empire*, Routledge, London.

Illner A., Davidson H. C., Harnsberger H. R., and Hoffman J. (2002), "The Silent Sinus Syndrome: Clinical and Radiographic Findings", *American Journal of Roentgenology*, Vol. 178, pp. 503–6.

Jackowski C., Bolliger S., and Thali M. J. (2008), "Common and Unexpected Findings in Mummies from Ancient Egypt and South America as revealed by CT", *RadioGraphics*, Vol. 28 (5), pp. 1477–92.

Jørgensen M. (2001), *Catalogue EGYPT III: Coffins, Mummy Adornments and Mummies from the TIP, LP, Ptolemaic and Roman Periods (1080 BC – AD 400)*, Ny Carlsberg Glyptotek, Copenhagen.

Kalampoukas K., Kyriazi S., Maravelia A., Tournas E., Couvaris C. M., Mihailidis G., Pantazis I., Lazaris P., Geroulanos S., and Bontozoglou N. (2020), "Crafting a Corpse, 'cheating' the Gods: A Composite Mummy from Ancient Egypt studied with Computed Tomography", *International Journal of Osteoarchaeology*, in press.

Kanawati N. (1980–1992), *The Rock Tombs of El-Hawawish: The Cemetery of Akhmim*, Vol. I–X, Macquarie Ancient History Association, North Ryde, NSW.

Klales A. R. (2014), *Computed Tomography Analysis and Reconstruction of Ancient Egyptians originating from the Akhmim Region of Egypt: A Biocultural Perspective* (PhD Thesis), University of Manitoba, Winnipeg MB (Canada).

Kuhlmann K. P. (1983), *Materialien zur Archäologie und Geschichte des Raumes von Achmim*, Philipp von Zabern, Mainz.

Lang P. (2012), *Medicine and Society in Ptolemaic Egypt*, (Studies in Ancient Medicine, 41), Brill, Leiden.

Lefebvre G. (1924), *Le tombeau de Petosiris* T. III, Publications du Service des Antiquités de l'Égypte, Cairo.

Lewin P. K. and Harwood-Nash D. C. (1977), "Computerized Axial Tomography in Medical Archaeology", *Palaeopathology Newsletter*, No. 17, pp. 8–9.

Lloyd A. B. (2002), "The Ptolemaic Period (332–30 BC)", I. Shaw (ed.), *The Oxford History of Ancient Egypt*, 2nd Ed., Oxford University Press, Oxford.

Loynes R. (2015), *Prepared for Eternity: A Study of Human Embalming Techniques in Ancient Egypt using Computerized Tomography Scans on Mummies*, Archaeopress Egyptology, 9, Archaeopress, Oxford.

Luger G. F. (2005), *Artificial Intelligence Structure and Strategies for Complex Problem Solving*, Addison-Wesley, Boston MA.

Lurker M. (1986), *The Gods and Symbols of Ancient Egypt: An Illustrated Dictionary*, 4th Ed., Thames & Hudson, London.

Maravelia A.-A. (2002), "“Ὅτι πλεῖστα θωμάσια <Αἴγυπτος> ἔχει καὶ ἔργα λόγου μέζω παρέχεται πρὸς πᾶσαν χώραν ... Egyptian Collections in Hellenic Museums: A Brief History and Some Pieces", A.-A. Maravelia (ed.), *Ancient Egypt and Antique Europe: Two Parts of the Mediterranean World. Papers from a Session held at the 7th Annual Meeting of the EAA in Esslingen 2001*, BAR International Series, 1052, Archaeopress, Oxford, pp. 15–29.

Maravelia A.-A. (2005), “Among the Hidden Treasures of the National Archaeological Museum of Athens: Searching for Forgotten Mummies, 2”, A.-A. Maravelia (ed.), *Modern Trends in European Egyptology: Papers from a Session, held at the European Association of Archaeologists 9th Annual Meeting in St. Petersburg 2003*, BAR International Series, 1448, Archaeopress, Oxford, pp. 7–21.

Maravelia A. (2017), “Smart Informatics and Egyptology: A Modern Inter-Disciplinary Forum studying an Ancient Culture of Pre- and Proto-Scientific Logistics and Intelligence”, M. Roushdy, H. Shedid, and N. Bader (eds.), *Proceedings of the 8th IEEE International Conference on Intelligent Computing and Information Systems ICICIS 2017, December 5–7 2017*, Vol. 1, Faculty of Computers and Information Sciences / ^oAin Shams University, Cairo, pp. 11–20.

Maravelia A., Bontozoglou N. *et al.* (2015), “The CT-Scanning Project of the Hellenic Institute of Egyptology: Archaeological and Forensic Study of the 9 Ptolemaic Mummies from Panopolis at the Premises of the National Archaeological Museum in Athens”, M. Tomorad (ed.), *CECE VII – 7th European Conference of Egyptologists – Egypt 2015: Perspectives of Research, Zagreb, Croatia (2-7 June 2015): Abstracts’ Book*, University of Zagreb and Croatian Institute of History, Zagreb, pp. 32–3.

Maravelia A.-A. and Cladaki-Manoli E. (2004), “Among the Hidden Treasures of the National Archaeological Museum of Athens: Searching for Forgotten Mummies, 1”, A.-A. Maravelia (ed.), *Europe, Hellas and Egypt: Complementary Antipodes during the Late Antiquity: Papers from a Session, held at the European Association of Archaeologists 8th Annual Meeting in Thessaloniki 2002*, BAR International Series, 1218, Archaeopress, Oxford, pp. 5–20.

Marquez S., Lawson W., Mowbray K., Delman B. N. and Laitman J. T. (2015), “CT Examination of Nose and Paranasal Sinuses of Egyptian Mummies and Three Distinct Human Population Groups: Anthropological and Clinical Implications”, *The Anatomical Record*, No. 298 (6), pp. 1072–84.

Maspero, G. (1885), “3o. Fouilles d’Akhmîm”, *Bulletin de l’Institut Égyptien: Année 1884*, 2e Série, No. 5, Imprimerie Nouvelle J. Barbier & Cie, Le Caire; pp. 66–8.

Maspero, G. (1893), *Études de Mythologie et d’Archéologie Égyptiennes*, Tome 1er, Bibliothèque Égyptologique, E. Leroux Éditeur, Paris.

McKnight L. M., McCreesh N. C., and Gize A. (2014), “The Weird and the Wonderful – The Scientific Study of a Miniature Mummy”, *Papers on Anthropology*, Vol. 23, pp. 97–107.

McKnight L. M., Atherton-Woolham S. D., and Adams J. E. (2015), “Imaging of Ancient Egyptian Animal Mummies”, *Radio-Graphics*, Vol. 35, pp. 2108–20.

McNally S. (1981–1982), “Survival of a City: Excavations at Akhmim”, *Newsletter of the American Research Center in Egypt*, No. 116, pp. 26–30.

Michailidis G., Kyriazi S., Maravelia A., Tourna E., Couvaris C. M., Kalampoukas K., Pantazis I., Lazaris P., Geroulanos S., Kalogerakou K., and Bontozoglou N. (2019), “Chronic Maxillary Atelectasis under the Wrappings of an Egyptian Mummy”, *Annals of Otology, Rhinology and Laryngology*, Vol. 128, No. 12, pp. 1165–9.

Νεροῦτσος Τ. Δ. (1884), “Σημειώσεις ἐπὶ Δέκα Μομίαις Ἑλληνο-Ῥωμαϊκῆς καὶ Βυζαντινῆς (*sic!*) Ἐποχῆς”, *Ἀρχαιολογικὴ Ἐφημερίς*, Ἀθῆναι, col. 171–80 and Tab. 12.

Newberry P. E. (1912), “The Inscribed Tombs of Ekhmîm”, *Annals of Archaeology and Anthropology of the University of Liverpool*, Vol. 4, pp. 101–20.

Nunn J. F. (1996), *Ancient Egyptian Medicine*, British Museum Press, London.

Ogdon J. R. (1985–1986), “Some Notes on the Iconography of Min”, *Bulletin of the Egyptological Seminar*, Vol. 7, pp. 29–41.

Pahor A. L. (1992), “Ear, Nose and Throat in Ancient Egypt”, *The Journal of Laryngology & Otology*, Vol. 106, pp. 773–9.

Pantazis I., Kyriazi S., Maravelia A., Tourna E., Couvaris C. M., Kalampoukas K., Michailidis G., Lazaris P., Geroulanos S., and Bontozoglou N. (2020), “A Ptolemaic Mummy reveals Evidence of Invasive Dentistry in Ancient Egypt”, *The Anatomical Record*, *in press*.

Panzer S., Thompson R. C., Hergan K., Zink A. R., and Piombino-Masali D. (2018), “Evidence of Aortic Dissection and Marfan Syndrome in a Mummy from the Capuchin Catacombs of Palermo, Sicily”, *International Journal of Palaeopathology*, No. 22, pp. 78–85.

Partridge R. (1994), *Faces of Pharaohs: Royal Mummies and Coffins from Ancient Thebes*, British Museum Press, London.

Pawlak Z. (1991), *Rough Sets: Theoretical Aspects of Reasoning about Data*, Kluwer, Dordrecht.

Piombino-Masali D., Jankauskas R., Snitkuvienė A., McKnight L., Longo M., and Longo S. (2013–2014), “Radiological Assessment of

A. Maravelia, N. Bontozoglou, K. Kalogerakou, C. M. Couvaris, S. Geroulanos

two Pseudo-Mummies from the National Museum of Lithuania”, *Journal of the Society for Studies of Egyptian Antiquities*, Vol. 40, pp. 71–9.

Piombino-Mascali D., Jankauskas R., Snitkuvienė A., Rutkauskas T., and Sutherland M. L. (2016), “Radiological and Archaeological Investigation of a Mummy from Roman Egypt curated in the National Museum of Lithuania”, *Anthropologischer Anzeiger*, Bd. 73, pp. 69–79.

Ranke H. (1935–1977), *Die ägyptische Personennamen*, Bd. I–III, J. J. Augustin, Glückstadt, 1935–1977.

Raven M. J. and Taconis W. K. (2005), *Egyptian Mummies: Radiological Atlas of the Collections in the National Museum of Antiquities in Leiden*, Brepols Publishers, Turnhout.

Salem A. B. (2007), “Case Based Reasoning Technology for Medical Diagnosis”, *Proceedings of World Academy of Science, Engineering and Technology* 25, CESSE, Venice, pp. 9–13.

Salem A. B. and Katoua H. S. (2012), “Web-Based Ontology of Knowledge Engineering”, *Journal of Communication & Computer*, Vol. 9, pp. 516–22.

Salem A. B. and Voskoglou M. G. (2013), “Applications of the CBR Methodology to Medicine”, *Egyptian Computer Science Journal*, Vol. 37 (7), pp. 68–77.

Salter-Pedersen E. (2004), *The Myth of Eternal Preservation: Patterns of Damage in Egyptian Mummies* (MA Thesis), Louisiana State University / LSU Digital Commons / LSU Master’s Theses 967, Baton Rouge LA.

Schneider H. D. (1977), *Shabtis. An Introduction to the History of Ancient Egyptian Funerary Statuettes with a Catalogue of the Collection of Shabtis in the National Museum of Antiquities at Leiden* I–III, Collections of the National Museum of Antiquities at Leiden II, Rijksmuseum van Oudheden te Leiden, Leiden

Shore A. F. (1992), “Human and Divine Mummification”, A. B. Lloyd (ed.), *Studies in Pharaonic Religion and Society presented to J. G. Griffith*, Egypt Exploration Society, London, pp. 226–8.

Taylor J. H. (1996), *Unwrapping a Mummy*, University of Texas Press, Austin TX.

Taylor J. H. and Antoine D. (2014), *Ancient Lives New Discoveries: Eight Mummies, Eight Stories*, British Museum Press, London.

Tzachou-Alexandri O. (ed., et al.) (1995), *The World of Egypt in the National Archaeological Museum*, Kapon Editions, Ministry of Culture and Hellenic ICOM, Athens.

Uranić I. (2012), *Mumije: Znanost i Mit / Mummies: Science and Myth*, Arheološki Muzej u Zagrebu / Archaeological Museum of Zagreb, Zagreb.

Veisse A.-E. (2004), *Les "révoltes égyptiennes". Recherches sur les troubles intérieurs en Egypte du règne de Ptolémée III à la conquête romaine*, (Studia Hellenistica, 41), Peeters, Leuven; Paris, and Dudley, MA.

Wade A. D., Humanen J., Lawson B., Tampieri B. and Nelson A. J (2012), "Early Dental Intervention in the Redpath Ptolemaic Theban Male", *International Journal of Palaeopathology*, Vol. 2, pp. 217–22.

Walker S. and Bierbrier M. (1997), *Ancient Faces: Mummy Portraits from Roman Egypt*, British Museum Press, London.

Waterman D. A. (1986), *A Guide to Expert Systems*, Addison-Wesley, Boston MA.

White T. D. and Folkens P. A. (2005), *The Human Bone Manual*, Elsevier Academic Press, Burlington MA.

Zakrzewski S. (2014), "Palaeopathology, Disability and Bodily Impairments", R. Metcalf *et al.* (eds.), *Palaeopathology in Ancient Egypt and Nubia: A Century in Review*, Archaeopress Egyptology, 6, Archaeopress, Oxford, pp. 57–68.

Zweifel L., Büni T., and Rühli F. J. (2009), "Evidence-Based Palaeopathology: Meta-Analysis of PubMed-Listed Scientific Studies on Ancient Egyptian Mummies", *HOMO – Journal of Comparative Human Biology*, Vol. 60 (5), pp. 405–27.

*A. Маравелія, Н. Бонтозоглу, К. Калогераку,
К. М. Куваріс, С. Геруланос*

**ЗАСТОСУВАННЯ ШТУЧНОГО ІНТЕЛЕКТУ В ЄГИПТОЛОГІЇ:
АФІНСЬКИЙ ПРОЄКТ ІЗ ВИВЧЕННЯ МУМІЙ ЯК ПРИКЛАД
ЕФЕКТИВНОЇ МІЖДИСЦИПЛІНАРНОСТІ**

Автори представляють проєкт із вивчення мумій Грецького інституту єгиптології, що працює в тісній співпраці з Національним археологічним музеєм в Афінах та Афінським медичним центром, як характерний приклад міждисциплінарного вивчення та взаємодії не тільки між інтелектуальною інформатикою (ІІ) і – меншою мірою – штучним інтелектом (ШІ) і (архео-)медициною, але також і єгиптологією, й (архео-)криміналістикою. Обговорено деякі інтригуючі результати КТ-сканування п'яти з дев'яти мумій, досліджених у рамках Проєкту, і підкреслені інформаційні можливості, що використовуються в комп'ютерній томографії (КТ), яка відкриває нові можливості у вивченні умов, причин смерті

A. Maravelia, N. Bontozoglou, K. Kalogerakou, C. M. Couvaris, S. Geroulanos

й дає іншу цікаву інформацію, пов'язану з людьми, які померли в Стародавньому Єгипті приблизно 2100 років тому, під час епохи Птолемеїв. Автори продемонстрували характерну парадигму міждисциплінарного застосування електронних технологій у медицині для дослідження здоров'я давніх людей (на основі комп'ютерних обчислень), що дозволяє по-новому поглянути на єгиптологічне й археологічне вивчення їхнього теократичного суспільства.

Ключові слова: Стародавній Єгипет, мумії, похоронні звичаї, комп'ютерна томографія, неінвазивне картування тіла, (архео-)медицина, (архео-)криміналістика, інтелектуальна інформатика, штучний інтелект, міждисциплінарність

A. Maravelia, N. Bontozoglou, K. Kalogerakou,

C. M. Couvaris, S. Geroulanos

ПРИМЕНЕНИЕ ИСКУССТВЕННОГО ИНТЕЛЛЕКТА В ЕГИПТОЛОГИИ: АФИНСКИЙ ПРОЕКТ ПО ИЗУЧЕНИЮ МУМИЙ КАК ПРИМЕР ЭФФЕКТИВНОЙ МЕЖДИСЦИПЛИНАРНОСТИ

Авторы представляют проект по изучению мумий Греческого института египтологии, работающий в тесном сотрудничестве с Национальным археологическим музеем в Афинах и Афинским медицинским центром, как характерный пример междисциплинарного изучения и взаимодействия не только между интеллектуальной информатикой (ИИ) и – в меньшей степени – искусственным интеллектом (ИИ) и (архео-)медициной, но также и египтологией, и (архео-)криминалистикой. Обсуждены некоторые интригующие результаты КТ-сканирования пяти из девяти мумий, исследованных в рамках Проекта, и подчеркнуты информационные возможности, используемые в компьютерной томографии (КТ), которая открывает новые возможности в изучении условий, причин смерти и дает другую интересную информацию, связанную с людьми, которые умерли в Древнем Египте приблизительно 2100 лет назад, во время эпохи Птолемеев. Авторы продемонстрировали характерную парадигму междисциплинарного применения электронных технологий в медицине для исследования здоровья древних людей (на основе компьютерных вычислений), что позволяет по-новому взглянуть на египтологическое и археологическое изучение их теократического общества.

Ключевые слова: Древний Египет, мумии, погребальные обычаи, компьютерная томография, неинвазивное картирование тела, (архео-)медицина, (архео-)криминалистика, интеллектуальная информатика, искусственный интелект, междисциплинарность

Стаття надійшла в редакцію 27. 06. 2019